

Age determination of Iberian lynx (*Lynx pardinus*) using canine radiograph and cementum annuli enumeration

By SONIA C. ZAPATA, ROSA GARCIA PEREA, J. F. BELTRAN, P. FERRERAS, and M. DELIBES

Estación Biológica de Doñana, Consejo Superior de Investigaciones Científicas, Sevilla, Spain and Museo Nacional de Ciencias Naturales, Consejo Superior de Investigaciones Científicas, Madrid, Spain.

Receipt of Ms. 06. 02. 1996

Acceptance of Ms. 04. 11. 1996

Age estimation of individuals is necessary to assess population dynamics and to help managers in the conservation of endangered populations (JOHNSTON et al. 1987). Two methods are commonly used to determine the age of carnivores: counting of cementum annuli (CCA) and measurement of canine pulp cavity (CPC) (GRUE and JENSEN 1979; JOHNSTON et al. 1987). The CCA method is based on the yearly addition of a layer of cementum on the outer surface of the tooth root (JOHNSTON et al. 1987; KLEVEZAL and KLEINENBERG 1967). The CPC technique relies on the progressive accumulation of dentine in the pulp cavity, which tends to narrow with age (JOHNSTON et al. 1987). The aim of the present study was to determine the feasibility of these complementary age techniques for the endangered Iberian lynx (*Lynx pardinus*). The age of closure of canine apical foramen will be also estimated.

We studied 89 Iberian lynx skulls from the collections of the Estación Biológica de Doñana, Seville, Spain, the Museo Nacional de Ciencias Naturales, Madrid, Spain, and the Natural History Museum, London, United Kingdom. Most of the specimens came from Doñana National Park (n = 58) (SW Spain), Sierra Morena (n = 10) (SW Spain), and Montes de Toledo (n = 21) (Central Spain). These three areas contain approximately 75% of the estimated total wild population of this species (RODRIGUEZ and DELIBES 1992). Dead specimens were found coincidentally with ongoing studies; others were confiscated from poachers. The age of 7 individuals was known, based on registered birth dates (within a month) when radio-tracking after capture until their death. We also knew the minimum age of another sample of 14 individuals whose age was unknown at capture (although according to their weight 7 were yearlings and 7 were adults; see BELTRAN and DELIBES 1993) and which were radio-tracked until their death. In order to estimate the age in months we assumed that all the individuals were born in April.

The lower left canine was extracted (after boiling mandibles) from 46 skulls (Tab. 1) and radiographed to measure pulp cavity at the point of its maximum width and canine diameter to the nearest 0.1 mm using a caliper. Then, we calculated the ratio of pulp cavity to canine width as a percentage. The open or closed condition of apical foramen was recorded for each extracted canine. Cementum annuli were counted on the third upper incisor (I³) of 38 skulls. The incisors were decalcified in a 5% solution of nitric acid, sectioned at 20 µm thickness with a cryostat, and stained with Ehrlich hematoxylin (KLEVEZAL and KLEINENBERG 1967). We also analysed cementum annuli counts in 57 lower canines (prepared by Matson's Laboratory, Milltown, Montana). Enumeration of cementum annuli from canines and incisors of the same six animals were compared. Finally, we compared values of pulp cavity ratios with age estimates from counts of cementum an-

Table 1. Summary of methods applied for age determination and Iberian lynx specimens studied (n). Specimens include a sample of known-age individuals (known birth date \pm 1 month), and minimum known-age individuals (age unknown when captured but radio tracked until death). Cementum annuli enumeration was performed in all the individuals, including the radiographed sample. I³: only incisor, C: only canine, I³ + C: incisor and canine.

	canine radiograph	cementum annuli count			n
		I ³	C	I ³ + C	
known age	4	5	0	2	7
minimum known age	8	11	0	3	14
unknown age	34	19	48	1	68
total	46	35	48	6	89

nuli. To determine whether there is an overlap between age-groups, pulp cavity data were plotted against annuli numbers, instead of relying on statistical tests which might be misleading (JOHNSTON et al. 1987).

Our observations on canines from 18 lynxes aged 10 to 22 months (including 5 known-age specimens) indicated that a closure of the apical foramen occurs at an age of 12 to 18 months. Incremental cementum annuli were recorded in 67 specimens (Fig. 1). In the remaining 22 individuals, no fully formed annuli were observed. The counts of cementum annuli in canines and incisors of the same animal were in agreement. The number of complete cementum annuli ranged between 1 and 13. We examined tooth sections of specimens younger than 24 months with closed apical foramen to establish the age of the formation of the first cementum annulus. An annulus in process of formation was observed in six specimens aged 18 to 22 months, whereas one 18-month old specimen did

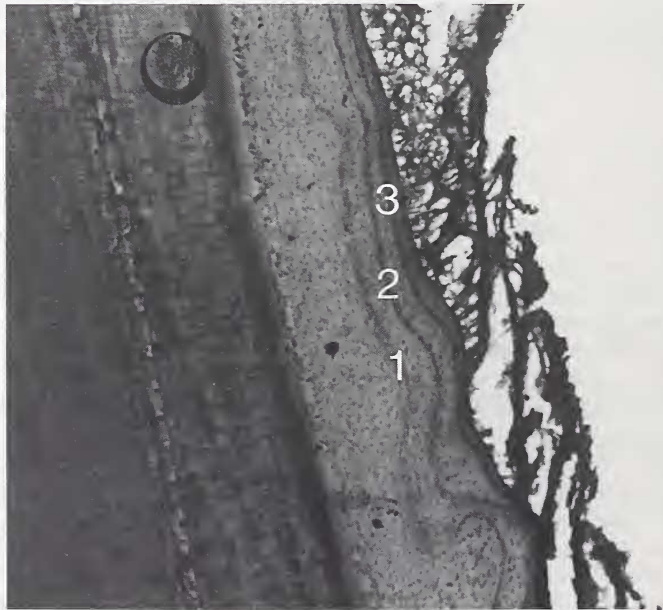


Fig. 1. Cementum annuli formed in a canine tooth of an Iberian lynx with a known age of 4 years from Doñana. Three annuli can be observed (1, 2 and 3).

not show any annulus. Similarly, a complete cementum annuli was observed in four specimens 24 months old (estimated age). Finally, one of two specimens 18 months old (known age) presented an annulus in process of formation, whereas there was no evidence of such a process in the other. In conclusion, the formation of the first complete cementum annuli probably starts around the 18th month of age, becoming apparent around the 22th month and being completed at about the 24th month of age. The formation period of this first complete annulus is from October to March.

An adult lynx (known age) born in spring 1985 and dying in August 1989 had three cementum annuli. On the other hand, all the 14 lynxes radio-tracked until their death had at least the minimum number of cementum annuli as expected from their known minimum age. These observations suggest that the formation of annuli occurs on a yearly basis. The oldest specimen of our sample was a male from Doñana. Its minimum age according to the radiotracking study was 7 years, but according to the enumeration of cementum annuli it was 14 years old.

The canine pulp cavity of two lynxes of known age 10 and 12 months was 73.3% and 60.9% of the canine width, respectively. In an 18-month specimen (known age) this percentage was 20.1%. In figure 2, the values of the canine pulp cavity ratios and the ages es-

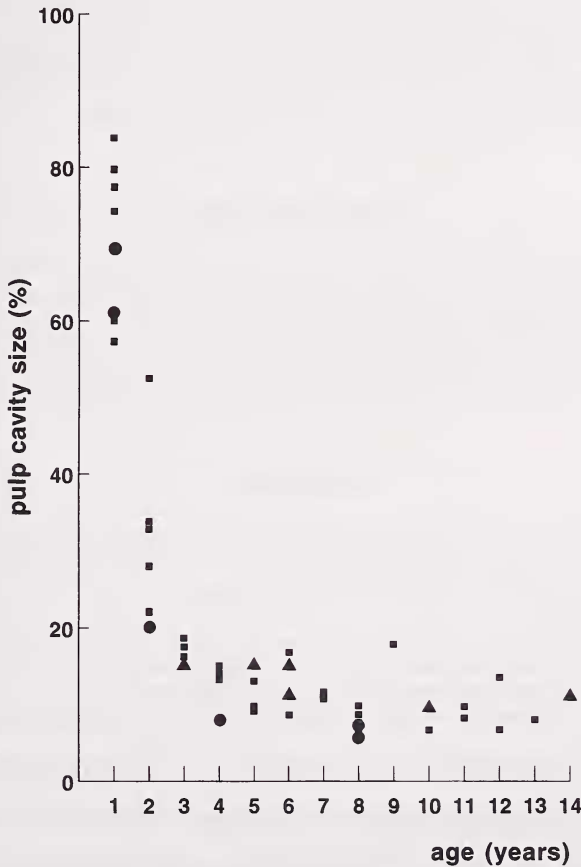


Fig. 2. Pulp cavity size expressed as a percentage of canine tooth width in relation to estimated age (cementum annuli) from our sample of Iberian lynxes. ■ lynxes with estimated age, ▲ lynxes with minimum known age and ● lynxes with known age.

timated by enumeration of cementum annuli are compared. The segregation of juveniles (less than 1 year and 1–2 years) from the remainder is clear, but it was not possible to separate age classes among the adults.

The time of closure of the canine apical foramen in the Iberian lynx agrees with published observations in bobcats (*Lynx rufus*) (CROWE 1972) and Canadian lynxes (*Lynx canadensis*) (BRAND and KEITH 1979). Nevertheless, in the Eurasian lynx (*Lynx lynx*) the complete closure of the apical foramen appears to occur at the 12th month of age (KVAM 1984). This criterion allows the separation of Iberian lynx juveniles from the other ages (see SAUNDERS 1963 and BRAND and KEITH 1979 for bobcat and Canadian lynx, respectively). Moreover, the method can be used on live anesthetized individuals via a simple radiograph of their canines. The canine pulp cavity width presents similar advantages. It appears to be adequate to separate juveniles from adults also in bobcats (JOHNSON et al. 1981), some canids (GRUE and JENSEN 1973, 1976) and some mustelids (JENKS et al. 1984; KUEHN and BERG 1981; DIX and STRICKLAND 1986).

The most accurate method for an age determination of adult Iberian lynxes in years is the enumeration of cementum annuli. The annual pattern of cementum deposition, as well as the period of formation of the first complete annulus, are similar to those detected by CROWE (1972) in the bobcat, by BRAND and KEITH (1979) in the Canadian lynx and by KVAM (1984) in the Eurasian lynx. Our observations on specimens of known-age confirm the reliability of estimating age in years by adding one to the number of complete cementum annuli. Some authors (BREITENMOSER et al. 1993) have estimated age of live-trapped individuals by counting the annuli of an incisor extracted from anesthetized Eurasian lynxes, with no apparent effects on the fitness of these individuals.

Acknowledgements

Funding was provided by Consejo Superior de Investigaciones Científicas (CSIC), and the Dirección General de Investigación Científica y Técnica (DGICYT) (projects PB87-0405, PB90-1018 and PB92-0121); Consejería de Educación de Madrid (fellowship to R.G.P.); CSIC and Junta de Andalucía (fellowships to J.F.B.). We thank the Estación Biológica de Doñana (CSIC), the Museo Nacional de Ciencias Naturales (CSIC), and the British Museum of Natural History for permission to examine specimens in their collections. A. GREEN, J. A. DONÁZAR and CLAUDIA KELLER also contributed to improve the manuscript.

References

- BELTRAN, J. F.; DELIBES, M. (1993): Physical characteristics of Iberian lynxes (*Lynx pardinus*) from Doñana, southwestern Spain. *J. Mammalogy* **74**, 852–862.
- BRAND, C. J.; KEITH, L. B. (1979): Lynx demography during a snowshoe hare decline in Alberta. *J. Wildl. Manage.* **43**, 827–849.
- BREITENMOSER, U.; KAVCZENKY, P.; DÖTTERER, M.; BREITENMOSER-WÜRSTEN, C.; CAPT, S.; BERNHART, F.; LIBEREK, M. (1993): Spatial organization and recruitment of lynx (*Lynx lynx*) in a re-introduced population in the Swiss Jura Mountains. *J. Zool. (London)* **231**, 449–464.
- CROWE, D. M. (1972): The presence of annuli in bobcat tooth cementum layers. *J. Wildl. Manage.* **36**, 1330–1332.
- DIX, L. M.; STRICKLAND, M. (1986): Use of tooth radiographs to classify martens by sex and age. *Wildl. Soc. Bull.* **14**, 275–279.
- GRUE, H.; JENSEN, B. (1973): Annular structures in canine tooth cementum in red foxes *Vulpes vulpes* of known age. *Dan. Rev. Game. Biol.* **8**, 1–2.
- (1976): Annual cementum structures in canines teeth of arctic foxes (*Alopex lagopus*) from Greenland and Denmark. *Dan. Rev. Game. Biol.* **10**, 1–2.
- (1979): Review of the incremental lines formation in teeth and bones from mammals. *Dan. Rev. Game. Biol.* **11**, 1–48.

- JENKS, A.; BOWYER, R. T.; CLARK, A. G. (1984): Sex and age-class determination for fisher using radiographs of canine teeth. *J. Wildl. Manage.* **48**, 626–628.
- JOHNSON, N. F.; BROWN, B. A.; BOSOMWORTH, J. C. (1981): Age and sex characteristics of bobcat canines and their use in population assessment. *Wildl. Soc. Bull.* **9**, 203–206.
- JOHNSTON, D. H.; JOACHIM, D. G.; BACHMANN, P.; KARDONG, K. V.; STEWART, R. A.; DIX, L. M.; STRICKLAND, M. A.; WATT, I. D. (1987): Aging furbearers using tooth structure and biomarkers. In: *Wild Furbearer Management and Conservation in North America*. Ed by M. NOVAK, J. A. BAKER, M. E. OBBARD, and B. MALLOCH. Ontario, Canadá: Ministry of Natural Resources. Pp. 228–243.
- KLEVEZAL, G. A.; KLEINENBERG, S. E. (1967): Age determination of mammals from annual layers in teeth and bones. Transl. 1969. Jerusalem: Israel Program for Scientific Translations.
- KUEHN, D. W.; BERG, W. E. (1981): Use of radiographs to identify age-classes of fisher. *J. Wildl. Manage.* **45**, 1009–1010.
- KVAM, T. (1984): Age determination in European lynx (*Lynx lynx*) by incremental lines in tooth cementum. *Acta Zool. Fennica.* **171**, 221–223.
- RODRIGUEZ, A.; DELIBES, M. (1992): Current range and status of the iberian lynx *Felis pardina*, Temminck 1824, in Spain. *Biol. Conserv.* **61**, 189–216.
- SAUNDERS, J. K. (1963): Movements and activities of the lynx in Newfoundland. *J. Wildl. Manage.* **27**, 390–400.

Authors' addresses: SONIA C. ZAPATA, J. F. BELTRÁN, P. FERRERAS, and M. DELIBES, Estación Biológica de Doñana, Consejo Superior de Investigaciones Científicas, Apdo. 1056, E-41080 Sevilla, Spain; ROSA GARCÍA-PEREA, Museo Nacional de Ciencias Naturales Consejo Superior de Investigaciones Científicas, J. Gutiérrez Abascal 2, E-28006 Madrid, Spain.